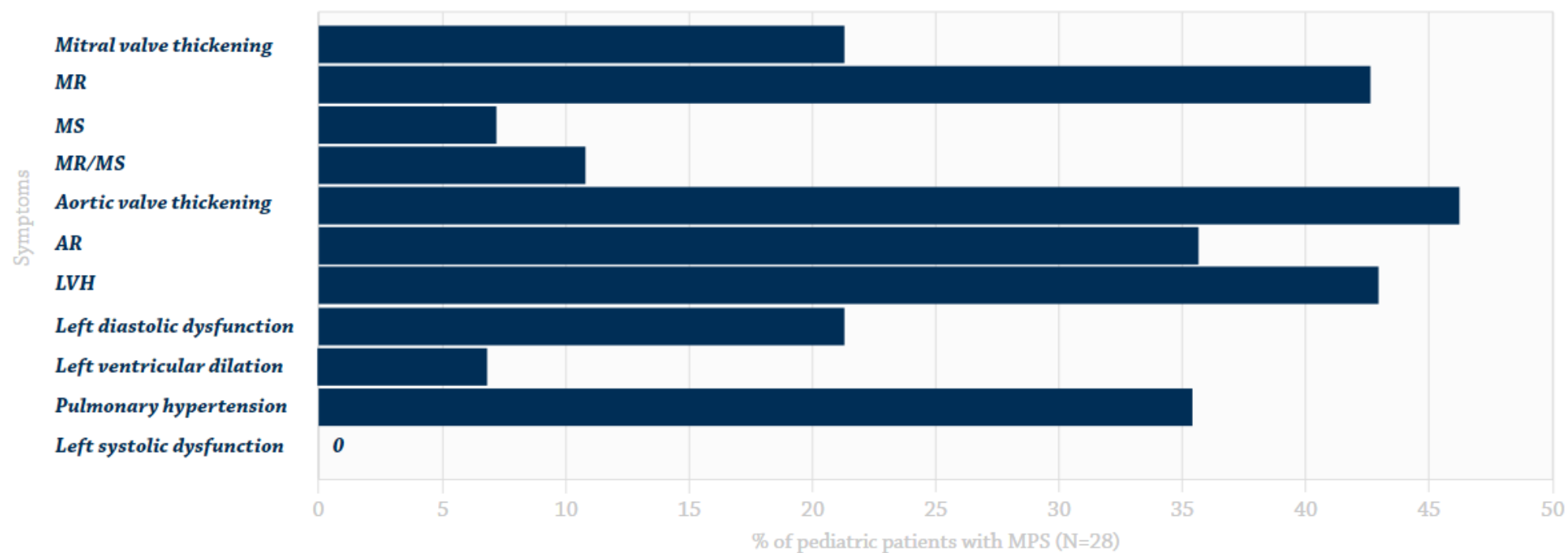


**Common cardiac symptoms from echocardiographic evaluation<sup>1,a</sup>**



Adapted from Braunlin, *J Inherited Metab Dis*, 2011.

Abbreviations: AR, aortic regurgitation; LVH, left ventricular hypertrophy; MR, mitral regurgitation; MS, mitral stenosis; MR/MS, both lesions.

<sup>a</sup>Evaluation in 28 patients with MPS I, II, III, IV, VI, and VII ages 2-14 years. The most common cardiac findings in these patients were left valve lesions, left ventricular hypertrophy, and pulmonary hypertension.